

## Imperforate Hymen with Hydrocolpos: A Case Report

Halimberdi Taneh<sup>1</sup>, Mahnaz Shahmiri<sup>2</sup>, Ghorban Mohammad Kouchaki<sup>3</sup>, Zahra Royani<sup>3</sup>, Maryam Chehregosha<sup>3</sup>,  
Ali Akbar Aghaeinejad<sup>3</sup>, \*Soheyla Kalantari<sup>3</sup>

<sup>1</sup> Department of Pediatric Surgery, Golestan University of Medical Sciences, Gorgan, Iran <sup>2</sup> Student Research Committee of Paramedicine School, Golestan University of Medical Sciences, Gorgan, Iran <sup>3</sup> Department of Surgical Technology, Faculty of Paramedicine School, Golestan University of Medical Sciences, Gorgan, Iran

### ABSTRACT

**Background:** Although the exact prevalence of vaginal atresia is unknown, studies show that this disorder is often accompanied with imperforate hymen associated with hydrocolpos. We report a 30-day-old infant with vaginal atresia and hydrocolpos secondary to imperforate hymen who underwent a two-stage vaginoplasty for treatment.

**Case description:** The patient was a 30-day-old female infant who was referred to the Taleghani Hospital in Gorgan with symptoms of abdominal distension and urinary retention, in 2016. Emergency laparotomy was performed. A large hydrocolpos was observed in the initial exploration. Fluid within the hydrocolpos was drained. A week later, the second surgery was performed for vaginal repair and hymen reconstruction. **Conclusions:** We performed a two-stage vaginoplasty that consisted hydrocolpos drainage in the first stage and hymen repair by cruciate incision in the second stage. Early use of imaging techniques and surgical treatment can prevent the secondary complications of the disorder such as hydronephrosis and sepsis.

**KEYWORDS:** vaginoplasty, hydrocolpos, vaginal atresia, imperforate hymen

\***Correspondence:** Soheyla Kalantari, Faculty of Paramedical Sciences, Golestna Univestiy of Medical Sciences, Gorgan, Iran, Telephone: +989354466840, Email: sa.kalantari@gmail.com

### INTRODUCTION

Congenital anomalies of the vagina such as vaginal atresia and imperforate hymen (IH) are classified as disorders of sex development (DSD). Vaginal atresia is caused by failure of connection between Müllerian ducts and urogenital sinus in the first trimester of the embryonic (organogenesis) period. The current prevalence of this disorder is not known [1]. IH is the most common cause of genital outflow tract obstruction with incidence rate ranging from 0.05 to 0.1% [2]. These congenital disorders usually lead to secondary complications such as hydrocolpos and hydrometrocolpos [3]. Congenital hydrocolpos is a rare condition that can present as pelvic mass, and involves vaginal dilation due to accumulation of mucus secretions and vaginal obstruction. Fluid accumulation can also lead to a wide

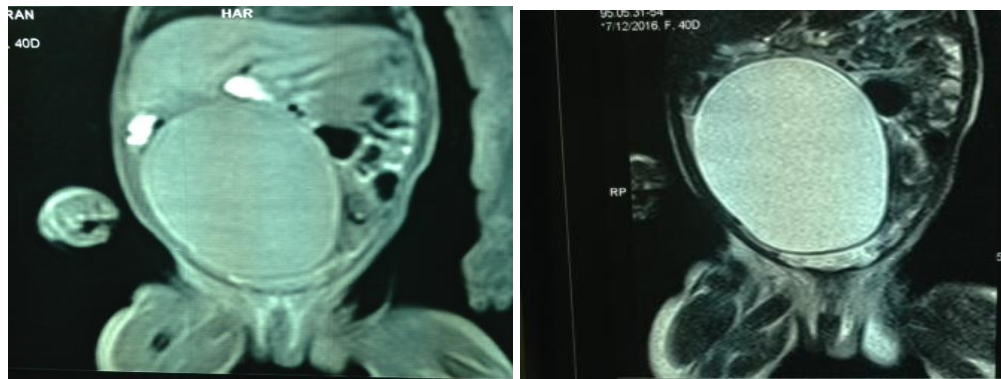
range of urogenital disorders such as hydronephrosis that can cause pressure on the bladder and ureter during infancy. Other secondary complications include gastrointestinal disorders [4]. Nowadays, various complex surgical and non-surgical techniques are used for vaginal reconstruction and IH-repair. Treatment of vaginal atresia can be performed using amnion graft, buccal mucosa graft, skin graft, a sigmoid colon segment, Frank's method of progressive perineal dilatation and combined techniques such as laparoscopy and balloon vaginoplasty. Disadvantages of these interventions include long recovery time, painful non-surgical treatment, and high complication rate for colon and skin grafting [5, 6]. Cruciate incision or other surgical procedures are used for treatment of hydrocolpos with the aim to protect the Bartholin's gland [7]. We

hereby report a case of two-step vaginoplasty for treatment of a 30-day old infant with vaginal atresia and hydrocolpos secondary to IH.

### CASE PRESENTATION

The patient was a 30-day-old female infant referred to Taleghani Hospital in 2016 with symptoms of abdominal distention and urinary retention. The patient was hospitalized in the neonatal intensive care unit. According to the mother, the baby had restlessness and frequent crying for a few days, and increased belly size along with decreased urination the day before admission. Nasogastric tube was placed to reduce abdominal distention. The patient was the first child of the family born by caesarian section at 36 weeks. Birth weight was 2.6 Kg, and the patient was breastfed by the mother. The patient had no family history of any specific disease. An abdominal mass was found during physical

examination. Necessary tests were performed and then surgical and nephrology consultation were requested for the patient. Results of electrolyte test were normal. MRI scan showed a lesion (dimensions  $77 \times 72 \times 56$  mm) in the pelvic cavity and bilateral moderate hydronephrosis (Figure1). Chest x-ray was normal. In addition, ultrasound scan showed mild to moderate bilateral hydronephrosis (left kidney more prominent). A large cystic lesion (65 mm in diameter) was found in the abdominopelvic cavity, especially on the right side, with fine diffuse internal echo, located exactly posterior to the bladder. Differential diagnosis indicated duplication cyst and a hydrocolpos. However, considering spreading to the pelvic floor and presence of a beak-like form in the lower aspects, the second diagnosis was more probable. Therefore, the patient went under a two-stage operation.

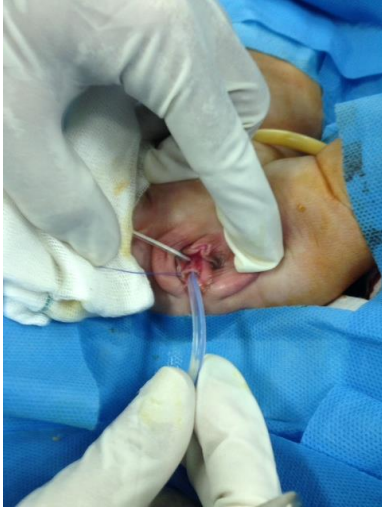

**Figure1. Distended vagina extending to perineum**

### *Surgical procedure*

The patient underwent general anesthesia in the supine position. Foley catheter was placed for the patient. In the first stage, emergency laparotomy was performed with cross section of the right upper quadrant. In the initial exploration, a large hydrocolpos was detected. Fluid within the hydrocolpos was drained. A drain was placed for the

hydrocolpos (Figure 2). A week after the first surgery and reduced drain fluid, the patient went under the second operation for vaginal repair and IH treatment under general anesthesia.



**Figure 2. Placement of a catheter into the urinary bladder and vagina**

After intraoperative injection of saline through the abdomen, the vaginal septum was evaluated from the outside. It was revealed that the vagina is closed and a lump was created from the vaginal septum from the outside. After aspiration and determination of the small thickness of the septum, cruciate incision was made on the septum and a Foley catheter was inserted. Three days after the surgery, the patient was discharged in good general condition.

## DISCUSSION

Congenital hydrocolpos is a rare condition with prevalence of 1 in 16,000 female births [8]. It usually involves fluid accumulation and vaginal obstruction due to stimulation of secretory glands. With increased severity and vaginal outlet obstruction, hydrocolpos can present as pelvic mass [4]. One of the main causes of hydrocolpos is IH, a congenital urogenital anomaly [3]. Incidence of IH is sometimes accompanied with Bardet-Biedl or McKusick-Kaufman syndromes. Nevertheless, non-syndromic cases have also been reported [2]. We presented a case of hydrocolpos secondary to IH and vaginal atresia. Based on the family history, the disorder was determined as non-syndromic.

JCBR. 2017; 1(3):20-24

Symptoms of hydrocolpos caused by vaginal atresia and IH can be presented as a wide range of gastrointestinal and urogenital disorders, which could complicate the diagnosis. These symptoms include nausea, dysuria, polyuria, urinary retention, abdominal pain, acute abdomen, abdominal mass and abdominal cysts [2,4,8-11]. In addition, other types of abdominal cysts such as ovarian cysts, mesenteric cysts and meconium cysts should be considered in the differential diagnosis [12]. The present case was admitted to the hospital with abdominal distension and urinary retention. Presence of an abdominal mass was confirmed by initial physical examination. According to Money Gupta et al., IH should be considered in any female newborn with a pelvic mass [12].

Vaginal atresia and IH are rarely diagnosed during infancy and usually occur during puberty [13]. The first diagnostic approach for hydrocolpos secondary to vaginal atresia and IH is physical examination of the genitalia for detection of the membrane in the vaginal opening [14]. Ultrasound scan is another diagnostic method that can be used. However, MRI, CT scan and contrast enhanced CT scan could be used for differential diagnosis. MRI is a useful, non-invasive, non-radiation imaging technique for infants. In such cases, MRI can clearly show anatomy of the perineum, septate uterus, septate vagina, fluid accumulation and IH [12,15]. Adaletli et al. (2007) diagnosed hydrocolpos in a fetus by detecting the exact location and extent of a cystic lesion using MRI [3]. Consistent with our results, several studies have shown that MRI can be used for accurate and definite diagnosis of hydrocolpos [2,4,12].

Surgical hymenectomy is the standard treatment for IH with X, T, cruciate and circular incisions. In this process, extra hymenal tissue is either removed or stitched to the vaginal wall. Then, a Foley catheter is placed for two weeks with estrogen cream to

form hymen and prevent scarring [7]. In this study, we performed a two-stage vaginoplasty to first drain hydrocolpos and then repair the hymen by making cruciate incisions. Hydronephrosis is one of the complications of hydrocolpos that has been reported by Murthy et al. (2013) in two newborns with hydrocolpos and hydronephrosis secondary to congenital vaginal atresia [4]. Moreover, some studies have shown that sepsis is also a serious complication in this group of patients. Some studies have reported infant mortality due to sepsis caused by hydrocolpos [16, 17].

### CONCLUSION

Hydrocolpos caused by IH and vaginal atresia is a rare disease in newborns, which is usually diagnosed as an abdominal mass. We performed a two-stage vaginoplasty that consisted hydrocolpos drainage in the first stage and hymen repair by cruciate incision in the second stage. Early use of imaging techniques, especially MRI, and surgical treatment could prevent the complications of this disorder.

### CONFLICT OF INTEREST

The authors declare that there is no conflict of interest.

### REFERENCES

1. Ostadian N, Razi T. A case report of a posterior sagittal vaginoplasty for the treatment of congenital vaginal atresia. *Medical Scientific Journal*. 2005;4(2):172-174.(In Persian).
2. Basaran M, Usal D, Aydemir C. Hymen sparing surgery for imperforate hymen: case reports and review of literature. *Journal of pediatric and adolescent gynecology*. 2009;22(4):e61-4.
- 3 Adaletli I, Ozer H, Kurugoglu S, Haluk E Madazli R. Congenital Imperforate Hymen with Hydrocolpos Diagnosed Using Prenatal MRI. *American Journal of Roentgenology*

2007;189(1):23-25.

4. Murthy V, Costalez J, Weiner J, Voos K. Two neonates with congenital hydrocolpos. *Case reports in pediatrics*. 2013;2013:692504.
5. Eftekhari T, Ghanbari Z, Foroghi far Z, Sheikh hosseini SH, Haghollahee F. Comparing Sexual Function in Normal Women and Women Having Undergone Vaginoplasty for Rokitansky Syndrome. *Journal of reproduction & infertility* .2010; 11(4):269-273.(In Persian).
6. Garcia-Roig M, Castellan M, Gonzalez J, Gorin M, Cruz-Diaz O, Labbie A Gosalbez R. Sigmoid Vaginoplasty with a Modified Single Monti Tube: A Pediatric Case Series. *J Urol*.2014; 191(5):1537-1542.
7. Ali A, Cetin C, Nedim C, Kazim G, Cemalettin A. Treatment of imperforate hymen by application of Foley catheter. *European journal of obstetrics, gynecology, and reproductive biology*. 2003;106(1):72-5.
8. Ayaz UY, Dilli A, Api A. Ultrasonographic diagnosis of congenital hydrometrocolpos in prenatal and newborn period: a case report. *Medical ultrasonography*. 2011; 13(3): 234-236.
9. Sakalkale R, Samarakkody U. Familial occurrence of imperforate hymen. *Journal of pediatric and adolescent gynecology*. 2005;18(6):427-9.
10. Aygun C, Ozkaya O, Ayyıldız S, Gungor O, Mutlu B, Kucukoduk S. An unusual cause of acute renal failure in a newborn: hydrometrocolpos. *Pediatric nephrology*. 2006;21(4):572-3.
11. Johal NS, Bogris S, Mushtaq I. Neonatal imperforate hymen causing obstruction of the urinary tract. *Urology*. 2009;73(4):750-1.
12. Gupta M, Bajwa SJS, Gupta M. Diagnostic dilemmas in management of neonatal hydrometrocolpos: A crucial role of magnetic resonance imaging. *Psychiatric Rehabilitation Journal*.2014;3(4):251-254.
13. Messina M, Severi FM, Bocchi C,

Ferrucci E, Di Maggio G, Petraglia F. Voluminous perinatal pelvic mass: a case of congenital hydrometrocolpos. *The Journal of Maternal-Fetal & Neonatal Medicine*. 2004;15(2):135-7.

14. Bajwa SJ, Kalra S. Logical empiricism in anesthesia: A step forward in modern day clinical practice. *Journal of Anaesthesiology Clinical Pharmacology*. 2013;29(2):160-1.

15. Tseng JJ, Ho JY, Chen WH, Chou MM. Prenatal diagnosis of isolated fetal hydrocolpos secondary to congenital imperforate hymen. *Journal of the Chinese Medical Association*. 2008;71(6):325-8.

16. Bischol A, Levitt MA, Breech L, Loudon E, Pena A. Hydrocolpos in cloacal malformations. *Journal of pediatric surgery*. 2010; 45( 6):1241–1245.

17. Hammad FT, Upadhyay VA. Neonatal infravesical obstruction in females. *Saudi Medical Journal*. 2005; 26(10):1630–1633.