

Case report

## Central Nervous System Tuberculosis Presenting As a Case of Myelitis: A Rare Complication

Nihar Ranjan Mohanty<sup>1\*</sup>, Bhagyashree Panda<sup>1</sup>

1. Faculty of Medicine, SCB Medical College, Cuttack, Odisha, India

\* **Correspondence:** Dr Nihar Ranjan Mohanty, Faculty of Medicine, SCB Medical College, Cuttack, Odisha, India

Tel: +9437326539

Email: [drniharmohanty07@gmail.com](mailto:drniharmohanty07@gmail.com)

Received April 1, 2021

Accepted July 6, 2021

### Abstract

**Background:** Transverse myelitis is an inflammatory disorder of the spinal cord manifested by acute or subacute onset of paraparesis, sensory deficit and autonomic dysfunction. Mycobacterium tuberculosis is a very rare cause of transverse myelitis. Diagnosis is made through clinical examination, cerebrospinal fluid analysis, magnetic resonance imaging (MRI) of spinal cord and bacteriological confirmation of infection. We report a case of tuberculoma presenting as transverse myelitis.

**Case description:** A 21 years old female presented with hypotonia of lower limbs, urine retention, no abdominal reflex and no deep tendon reflex in knee and ankle. Brain and spine MRI suggested multi tuberculomas and incomplete myelitis. The patient was recovered after treatment with antitubercular drugs and corticosteroids.

**Conclusion:** Our findings highlight the importance of considering tuberculosis infection when managing cases with longitudinal extensive transverse myelitis.

**Keywords:** Tuberculous myelitis; Transverse myelitis; Central nervous system; Tuberculosis

DOI: 10.29252/Jcbr.5.2.1



This work is licensed under a Creative Commons Attribution 4.0 License.

© The authors

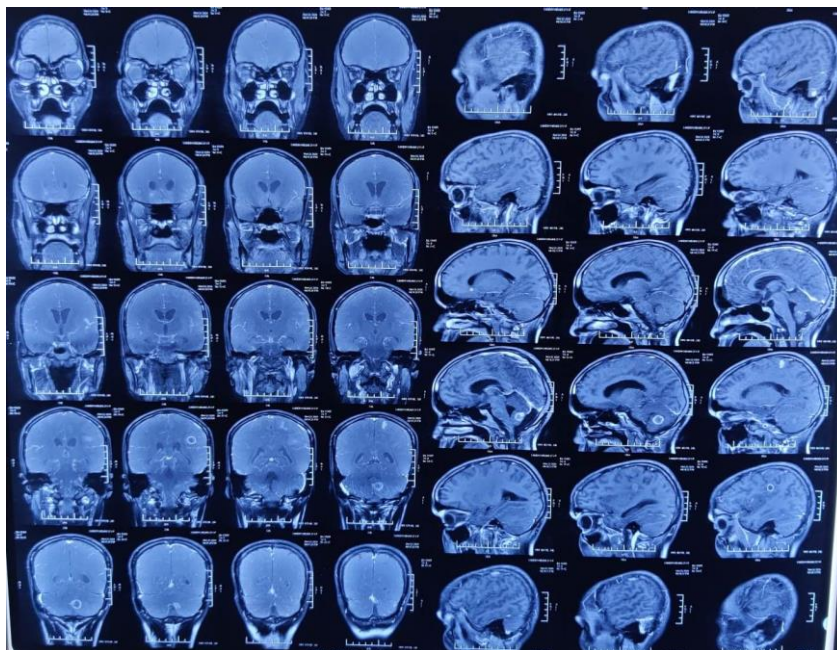
## INTRODUCTION

Both acute transverse myelitis and longitudinal extensive transverse myelitis have been described in patients with tuberculous meningitis. Acute transverse myelitis is an acute inflammatory process characterized by a segmental inflammation manifesting as functional transection of the cord with motor, sensory and bladder dysfunction below the level of the lesion (1). Longitudinal extensive transverse myelitis is characterized by a myelitis extending over three or more spinal segments.

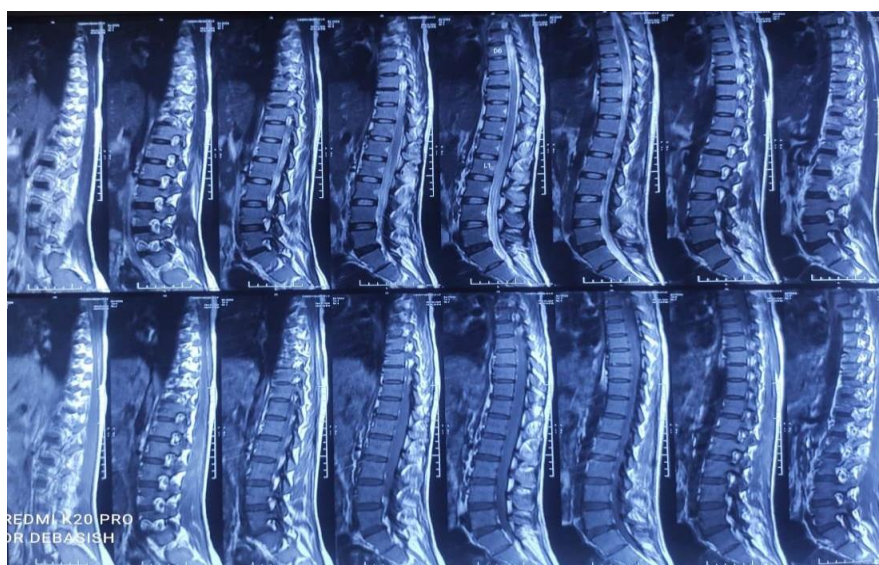
Tuberculous myelitis is usually associated with tuberculous intracranial involvement of the meninges or brain parenchyma or with tuberculous arachnoiditis of the spine. The condition often affects more than one spinal segment, particularly the thoracic and cervical region (1). This much of extensive involvement is usually rare and associated with greater risk of morbidity. An abnormal immune reaction against mycobacterial antigen is thought to be the main pathogenic mechanism. Tuberculous radiculomyelitis is a rare form of spinal tuberculosis (TB) (2). It may develop as a result of downward extension of TB, a secondary extension from vertebral TB and a primary TB lesion (3). Clinical features include subacute to chronic progressive flaccid paraparesis, positive Babinski sign that is preceded by root pain, paresthesia and bladder disturbance. Tubercular myelitis is confirmed by cerebrospinal fluid (CSF) analysis, radiological features and bacteriological confirmation. We present a rare case of tuberculoma progressing to myelitis that improved after treatment with antitubercular drugs and corticosteroids.

## CASE PRESENTATION

A 21 years old female presented with history of fever and vomiting for 15 days and focal convulsions with altered sensorium for five days. After three days of hospitalization, the patient suddenly developed weakness in both lower limbs with urine retention for which she was catheterized. She also developed constipation. There was no history of TB or spinal trauma. On examination, there was 7th cranial nerve palsy (upper motor neuron type). There was hypotonia of both lower limbs, muscle power was 2/5 (medical research council grade, MRC) in both lower limbs. Abdominal reflex was absent and Babinski reflex was positive for both lower limbs. Deep tendon reflex was absent in knee and ankle. Sensory examination was normal. Her routine blood tests were normal. CSF analysis revealed normal sugar (40mg/dl), very high protein (538mg/dl) and high adenosine deaminase (77.7 U/l). Brain magnetic resonance imaging (MRI) revealed multiple small to large (3mm to 15mm) supratentorial and infratentorial rim enhancing space occupying lesions with signal alteration with perifocal edema, suggesting multi tuberculomas (figure 1). Spinal MRI revealed D6-D8 segment subtle signal alteration suggesting incomplete myelitis (figure 2). The patient was treated with anti-tubercular medications as per protocol. She was given dexamethasone injection (8 mg tid) for two weeks. The patient's muscle power improved to MRC grade power of 4/5 after a week of treatment. Dexamethasone administration was tapered in a graded manner as she received the drug for a period of four weeks.



**Figure 1.** MRI Image of brain showing multiple supratentorial and infratentorial lesions suggesting tuberculoma



**Figure 2.** MRI image of dorsolumbar spine showing D6-D8 segment signal alteration suggesting incomplete myelitis

## DISCUSSION

TB is one of the common infections around the world with about 23% infected individuals worldwide in 2018 (<https://www.cdc.gov/globalhealth/newsroom/topics/tb/index.html>) Neurological involvement is a very serious complication of TB. Spine may be involved either as a primary lesion or as a downward extension

from brain TB or extension from vertebral TB. Among these, downward extension from intracranial TB is the most common cause of spinal involvement. Thoracolumbar region is the most commonly affected area followed by the cervical region (1). The space between the spinal dura mater and the leptomeninges is occupied with exudates,

which encases the spinal cord and impinge on the nerve roots. Infarction caused by thrombosis of the anterior spinal artery has been also reported (1). Tubercular myelitis may have an acute or sub-acute presentation. There are other reports available on longitudinal extensive transverse myelitis related to tuberculosis infection (3, 5).

Our case was presented with paraparesis or paraplegia, radicular pain and neurogenic bladder. The CSF analysis showed lymphocytic pleocytosis, hypoglycorrhchia and high protein level. MRI findings revealed enhancement of the dura-arachnoid complex around the cord and segmental enhancement of the cord, suggesting either infarction caused by vasculitis or TB myelitis in association with diffuse cord swelling. Treatment of tubercular myelitis involves medication with or without surgical intervention. Medication involves antitubercular treatment for nine to 12 months. Surgery can be considered if there is compression of spinal cord with neurological deficit. Corticosteroid is another adjuvant therapy, which is given for a period of four weeks.

## CONCLUSION

Longitudinal extensive transverse myelitis is a well-known but rare complication of neuronal TB infection, which is manageable with anti-tuberculosis drugs and corticosteroid treatment. Our findings highlight the importance of consideration of TB when diagnosing and treating patients with CNS tuberculoma and longitudinal extensive transverse myelitis.

## ACKNOWLEDGMENTS

None.

## DECLARATIONS

### Funding

Not applicable.

## Ethics approvals and consent to participate

Consent was obtained from the patient for publication after ensuring confidentiality of personal information.

## Conflict of interest

The authors declare that there is no conflict of interest regarding publication of this article

## REFERENCES

1. Garg RK, Malhotra HS, Gupta R. Spinal cord involvement in tuberculous meningitis. *Spinal Cord*. 2015;53(9):649-57. [[View at Publisher](#)] [[DOI:](#)] [[PubMed](#)] [[Google Scholar](#)]
2. Putruele AM, Legarreta CG, Limongi L, Rossi SE. Tuberculous transverse myelitis: Case report and review of the literature. *Clinical Pulmonary Medicine*. 2005;12(1):46-52. [[View at publisher](#)] [[DOI](#)] [[Google](#)] [[View at Publisher](#)] [[DOI:](#)] [[Google Scholar](#)]
3. Sahu SK, Giri S, Gupta N. Longitudinal extensive transverse myelitis due to tuberculosis: a report of four cases. *Journal of postgraduate medicine*. 2014;60(4):409-412. [[View at Publisher](#)] [[DOI:](#)] [[PubMed](#)] [[Google Scholar](#)]
4. Zhang Y, Zhu M, Wang L, Shi M, Deng H. Longitudinally extensive transverse myelitis with pulmonary tuberculosis: two case reports. *Medicine*. 2018;97(3): e9676. [[View at Publisher](#)] [[DOI:](#)] [[PubMed](#)] [[Google Scholar](#)]
5. Ortega-Rosales A, Delgado-Torres N, Burneo-Rosales C. A rare neurological complication of tuberculosis: Transverse myelitis. *IDCases*. 2019;17:e00564 [[View at Publisher](#)] [[DOI:](#)] [[PubMed](#)] [[Google Scholar](#)]

**How to Cite:** Mohanty N R, Panda B. Central Nervous System Tuberculosis Presenting As a Case of Myelitis: A Rare Complication. *Journal of Clinical and Basic Research*. 2021; 5 (2) :1-5