

## Case Report

# Bilateral Pheochromocytoma Presenting with Only Gastrointestinal Complaints: A Case Report

Alireza Norouzi<sup>1</sup>, Abdolreza Fazel<sup>1</sup>, Samaneh Tavassoli<sup>1</sup>, Fatemeh Mohammadzadeh<sup>1\*</sup>

<sup>1</sup>Golestan Research Center of Gastroenterology and Hepatology (GRCGH), Golestan University of Medical Sciences (GOUMS), Iran

### ABSTRACT

**Introduction:** Pheochromocytoma is a rare catecholamine-secreting tumor with gastrointestinal manifestations. **Case description:** Herein, we report a 50 years old female patient with abdominal pain, altered bowel habit, abdominal mass lesion and laboratory features of pheochromocytoma. The patient was admitted with abdominal pain, back pain, arthralgia, weakness, lethargy, cold sweat and weight loss. She had history of diabetes mellitus, ischemic heart disease and hyperlipidemia. On admission, she was normotensive and had normal physical examination. Upper and lower endoscopies were normal. Transabdominal sonography and CT scan showed large heterogeneous masses with central necrosis and calcification in adrenal regions. In addition, 24-hour urine evaluation showed elevated vanillylmandelic acid, metanephrine and normetanephrine levels. She underwent bilateral adrenalectomy. Pathologic evaluation showed typical characteristics of pheochromocytoma. **Conclusions:** In any patient with abdominal pain and abdominal mass, low threshold for diagnosis of rare but often lethal pheochromocytoma is suggested.

**KEYWORDS:** pheochromocytoma, constipation, abdominal pain

**\*Correspondence:** Fatemeh Mohammadzadeh, Address: Golestan Research Center of Gastroenterology and Hepatology (GRCGH), Golestan University of Medical Sciences (GOUMS), Iran, Telephone: +98-9123305219, Email: msoheila66@yahoo.com

### INTRODUCTION

Catecholamine-secreting tumors that arise from chromaffin cells of the adrenal medulla and the sympathetic ganglia are referred to as pheochromocytomas and catecholamine-secreting paragangliomas (extra-adrenal pheochromocytomas), respectively [1]. The prevalence of pheochromocytomas in patients suffering from hypertension has been reported as 0.1–0.2%. The clinical signs and symptoms of pheochromocytomas are highly variable. Hypertension is the most common symptom, followed by tachycardia, sweating and headache. Gastrointestinal presentations are very rare in pheochromocytoma [2]. Moreover, 90% of pheochromocytomas are located in the adrenal gland in adults, while the rest are extra-adrenal pheochromocytomas [3]. Since the tumors share similar clinical features and treatment approaches, the term "pheochromocytoma"

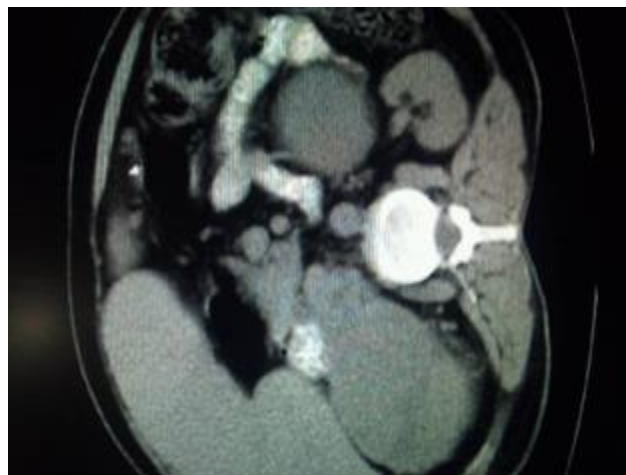is used by many clinicians to refer to both adrenal pheochromocytomas and catecholamine-secreting paragangliomas. Nevertheless, the distinction between pheochromocytoma and paraganglioma is important because of the implications for associated neoplasms, risk of malignancy, and genetic testing [4]. Episodic symptoms may occur in spell or paroxysms that can be extremely variable in presentation, but may typically include forceful heartbeat, pallor, tremor, headache and diaphoresis. Patients whose pheochromocytoma is diagnosed in the presymptomatic stage may have normal blood pressure [5]. Although gastrointestinal symptoms of pheochromocytoma such as abdominal pain, nausea and vomiting have been frequently reported, presence of these symptoms at the time of disease presentation without history of hypertension or other classic symptoms and signs is rare [2].

Sustained high catecholamine levels secreted by a high tumor burden may explain the mechanism by which constipation, paralytic ileus and megacolon occur in association with pheochromocytoma. The effects of catecholamines on intestinal smooth muscle and the splanchnic circulation are well demonstrated. Stimulation of  $\alpha$ -receptors causes hyperpolarization and relaxation of intestinal smooth muscle, constriction of intestinal vascular smooth muscle and contraction of ileocolic sphincters. Stimulation of  $\beta$ 2-receptors causes arteriolar dilatation and intestinal smooth muscle relaxation. Therefore, high levels of circulating catecholamines may lead to decreased intestinal peristalsis, motility and tone. Clinically, this may manifest initially as intermittent constipation [6]. Early diagnosis of the gastrointestinal manifestations of pheochromocytoma may be helpful in preventing diagnostic error and possible lethal outcomes. In this study, we report a patient with bilateral adrenal pheochromocytoma presenting only with gastrointestinal symptoms.

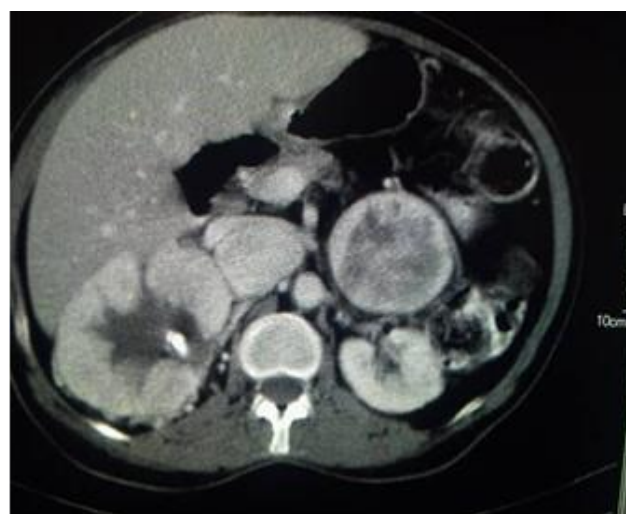### CASE PRESENTATION

A 50 years old woman was evaluated for abdominal pain that had started three months ago. The pain was in the epigastric region and was not related to food consumption but became aggravated with sitting or walking. She also had nausea, cold sweating, constipation and weight loss. The patient had history of diabetes mellitus (since 11 years ago), coronary heart disease (since 6 months ago), cholecystectomy and appendectomy (20 years ago). Physical examination revealed normal blood pressure and heart rate with no anomaly in face, extremities or chest. Abdomen was soft without tenderness and guarding. No organomegaly or mass was detected. Laboratory test results showed mild anemia

and elevated erythrocyte sedimentation rate. Urinalysis and stool exams were normal. The patient had normal renal and thyroid function. In addition, levels of sodium, potassium, calcium, phosphorus, and alkaline phosphatase were normal. Upper Gastrointestinal (GI) endoscopy and total colonoscopy were normal. Computed tomography (CT) scan demonstrated masses in both adrenal glands with diameters of 6 and 12 cm (Figures 1a and 1b).



**Figure 1a:** CT scan of the abdomen in the presented case (sagittal cut-off) without contrast



**Figure 1b:** CT scan of the abdomen in the presented case (sagittal cut-off) with contrast

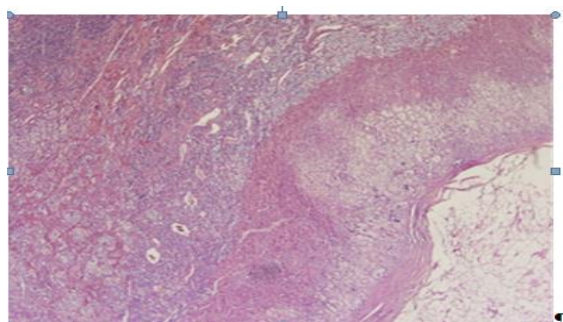
Results of 24-hour urine collection test are

shown in table 1. Plasma level of cortisol, dehydroepiandrosterone sulfate, androstenedione and urine free cortisol were normal.

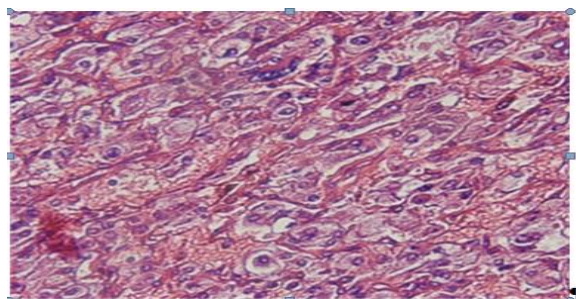
**Table 1: Results of 24-hour urine collection test**

Test	Patient's result	Normal range
Normetanephrine level	4090 microgram/24 h	50-600
Metanephrine level	5.9 mg/24 h	up to 1 mg/24 h
Vanillylmandelic acid level	31.9 mg/24 h	<13.6 mg/24 h

Probable diagnosis of bilateral pheochromocytoma was made, and no metastatic lesion to other organs was found in imaging. The patient started receiving 10 mg phenoxybenzamine twice daily. After two weeks, she underwent open bilateral adrenalectomy since no other site of involvement was found during the operation. The histopathologic features were consistent with bilateral adrenal pheochromocytoma (Figures 2a, 2b). Postoperative period was uneventful and the patient was discharged after three weeks.



**Figure 2a: Microscopic view of the specimen (hematoxylin-eosin stain, magnification ×40)**



**Figure 2b: Microscopic view of the specimen (hematoxylin-eosin stain, magnification ×100)**

## DISCUSSION

We hereby reported a case of pheochromocytoma that was presented only with abdominal pain and constipation, without history of hypertension or any other typical symptoms. Excessive levels of circulating catecholamines released from the pheochromocytoma, induced intestinal smooth muscles to dilate and decreased intestinal peristalsis, motility and tone via  $\alpha$ -adrenergic receptors [6-7]. In addition, catecholamines may induce vasoconstriction of the mesenteric vessels, leading to ischemic change [6] and intestinal necrosis [8-9]. Pheochromocytoma associated with refractory constipation has been previously reported [10-11].

Catecholamines liberated from pheochromocytoma may play an important role in the pathogenesis of the condition through digestive adrenergic receptors. The typical gastrointestinal manifestations of pheochromocytoma include nausea, vomiting and abdominal pain, but constipation has been reported in 5-13% of cases [12].

In 2012, Zulmeri reported a 43 years old man with pheochromocytoma and history of abdominal distension associated with nausea, vomiting and a pressure sensation on the epigastric part of the abdomen. Abdominal CT scan showed right adrenal gland mass [13]. In another report by Shah and Reiser, a patient was presented with abdominal pain after walking, exercise and significant weight loss. They found a large intensely enhancing mass in the

retroperitoneum, and laboratory markers confirmed the diagnosis of pheochromocytoma [14].

A cohort study in Germany (2009) indicated that the number of incidentally discovered pheochromocytoma cases is increasing (almost by 30%) owing to better availability of imaging techniques. Moreover, patients with incidentally detected pheochromocytoma are older than symptomatic cases. In the mentioned study, weight loss, nausea, vomiting and abdominal pain were reported in 17.3%, 14.5% and 15.1% of cases, respectively [15].

In previous cases, abdominal pain and constipation have been due to acute events including megacolon [16-17] or paralytic ileus [18] and pseudo-obstruction [19-20]. Other causes include pancreatitis, cholecystitis or perforation and bleeding [21-23].

Similar to other cases, our case was in the upper age group and had gastrointestinal symptoms accompanied by weight loss. However, she did not have any features of catecholamine excess or chronic hypertension that was persistent or associated with the gastrointestinal symptoms in the previous reports.

It has been reported that familial pheochromocytoma could be found in multiple endocrine neoplasia (MEN) IIa (Sipple syndrome) which causes thyroid medullary carcinoma and concomitant parathyroid adenoma or hyperplasia [24], or MEN IIb (Wermer syndrome) which causes mucosal neuroma of the eyelid, lip and tongue and sometimes showing the marfanoid physique [25]. However, involvement of hereditary factors was unclear in our case because no gene analysis was performed. No morphological change was noted in the thyroid, face or physique. In addition, thyroid sonography and serum level of calcium, phosphorus and

parathyroid hormone were normal. Therefore, it was thought that the present case has no concern with these conditions.

## CONCLUSION

For patients with abdominal pain and abdominal mass, low threshold for diagnosing rare but often lethal pheochromocytoma is suggested.

## REFERENCES

1. Yau JS, Li JK, Tam VH, Fung LM, Yeung CK, Chan KW, et al. Pheochromocytoma in the Hong Kong Chinese population. *Hong Kong Med J.* 2010;16(4):252-6.
2. Kek PC, Ho ETL, Loh LM. Pheochromocytoma presenting with pseudo-intestinal obstruction and lactic acidosis. *Singapore Med J.* 2015; 56(8): e131-e133.
3. Kumar P, Ghosh S, Tanwar HS, Gupta AK. Acrocyanosis in a young adult: a rare presentation of extra-adrenal pheochromocytoma. *BMJ Case Rep.* 2014.
4. Van Berkel A, Lenders JW, Timmers HJ. Diagnosis of endocrine disease: Biochemical diagnosis of pheochromocytoma and paraganglioma. *Eur J Endocrinol.* 2014;170(3):R109-19.
5. Williams Textbook of Endocrinology 12<sup>th</sup> Edition. vol1: 548-549.
6. Goodman L, Gilman A. The pharmacologic basis of therapeutics. New York: MacMillan. 1985; 14.
6. Turner CE. Gastrointestinal pseudo-obstruction due to pheochromocytoma. *Am J Gastroenterol.* 1983;78:214-7.
7. Salazar A, Naik A, Rolston DD. Intestinal pseudoobstruction as a presenting feature of a pheochromocytoma. *J Clin Gastroenterol.* 2001;33:253-4.
8. Sohn CI, Kim JJ, Lim YH, et al. A case of ischemic colitis associated with pheochromocytoma. *Am J Gastroenterol.* 1998;93:124-6.



9. Szmulowicz UM, Savoie LM. Ischemic colitis: an uncommon manifestation of pheochromocytoma. *Am Surg.* 2007;73:400-3.
10. Short IA, Padfield PL. Malignant phaeochromocytoma with severe constipation and myocardial necrosis. *Br Med J.* 1976;2:793-4.
11. Thurttle OA, Allen AP, Walters MT, et al. Intractable constipation in malignant pheochromocytoma: combined treatment with adrenergic blockade and cholinergic drugs. *Royal Soc Med.* 1984;77:327-8.
12. Gifford RW, Kvale WF, Maher FT, Roth GM, Priestley JT. Clinical features, diagnosis and treatment of pheochromocytoma: a review of 76 cases. *Mayo Clin Proc.* 1964; 39:281-302.
13. Zulmari CS, Juan CC, Ortiz-Betancourt JM, An unusual presentation of pheochromocytoma. *Crit Care & Shock.* 2011; 14:46-51.
14. Shah D, Reiser J. Chronic Abdominal Pain: "The Great Masquerader". *Practical Gastroenterology*; December 2010.
15. Kopetschke R, Slisko M, Kilisli A, et al. Frequent incidental discovery of pheochromocytoma: data from a German cohort of 201 pheochromocytoma. *European Journal of Endocrinology.* 2009; 161: 355–361.
16. Duffy TJ, Erickson EE, Jordan GL, Bennett HD. Megacolon and bilateral pheochromocytoma. *Am J Gastroenterol.* 1962; 38:555–563.
17. Suba AR. Bilateral pheochromocytoma with megacolon. *Mol Med.* 1971; 68:256 – 258.
18. Francis RS. X-Ray of the month. *J Tenn Med Assoc.* 1976; 69:114 –142.
19. Cruz SR, Colwell JA. Pheochromocytoma and ileus. *JAMA.* 1972; 219:1050 –1051.
20. Mullen JP, Cartwright RC, Tisherman SE, Misage JR, Shapiro AP. Case report: pathogenesis and pharmacologic management of pseudo-obstruction of the bowel in pheochromocytoma. *Am J Med Sci.* 1985; 290:155–158.
21. Turner CE. Gastrointestinal pseudo-obstruction due to pheochromocytoma. *Am J Gastroenterol.* 1983; 78:214 –217.
20. Sweeney AT, Malabanan AO, Blake MA, de las Morenas A, Cachecho R, Melby JC. Megacolon as the presenting feature in pheochromocytoma. *J Clin Endocrinol Metab.* 2000;85:3968-72.
22. Kolhe N, Stoves J, Richardson D, Davison AM, Gilbey S. Hypertension due to phaeochromocytoma an unusual cause of multiorgan failure. *Nephrol Dial Transplant.* 2001;16:2100-4.
23. Brouwers FM, Eisenhofer G, Lenders JW, Pacak K. Emergencies caused by pheochromocytoma, neuroblastoma, or ganglioneuroma. *Endocrinol Metab Clin North Am.* 2006;35:699-724.
24. Kousseff BG. Multiple endocrine neoplasia 2 (MEN 2)/MEN 2A (Sipple syndrome). *Dermatol Clin.* 1995;13:91.
25. Wohlk N, Schweizer H, Erlic Z, Schmid KW, Walz MK, Raue F, et al. Multiple endocrine neoplasia type 2. *Best Pract Res Clin Endocrinol Metab* 2010;24:371–87.