

Case Report

Clinical and Histopathological Evaluations of Testicular Regression Syndrome: A Case Report

Sabry Nasr Ali^{*1,2} , Amany Mohammed Rabie Mohammed Omar^{3,4}, Husam Alhama-dan^{5,6}

1. Department of Paediatrics, Faculty of Medicine, Minia University, Minia, Egypt
2. Hamad Medical Corporation, Doha, Qatar
3. Department of Pathology, Faculty of Medicine, Minia University, Minia, Egypt
4. Al Emadi Hospital, Doha, Qatar
5. Department of Paediatric Surgery, Pediatric University Hospital, Damascus, Syria
6. Al Emadi Hospital, Doha, Qatar

***Correspondence:** Dr. Sabry Nasr Ali, Hamad Medical Corporation, Doha, Qatar

Tel: +97466130108

Email: sabrynasrally@yahoo.com

Received Feb 02, 2020

Accepted Mar 11, 2020

Abstract

Background: Testicular regression syndrome (TRS) is defined as the partial or total absence of testicular tissue in 46XY patients with normal external genitalia. The incidence of TRS has been reported to be less than 5% in patients with cryptorchidism. Herein, we report a case of a one-year old boy who underwent surgical exploration with an initial diagnosis of cryptorchidism.

Case description: a one-year old male came to the outpatient clinic at Al Emadi Hospital, Doha, Qatar. Physical examination revealed normal external genitalia with palpable right testis and non-palpable left testis. The initial diagnosis was cryptorchidism. Testicular structure was not identified and a presumed testicular remnant in the left superficial inguinal ring was sent for histological examination. The histological examination revealed a fibrovascular nodule, spermatic cord structures, calcification and hemosiderin deposits supporting the diagnosis of TRS.

Conclusion: When patient fulfills clinical and pathological criteria for TRS, we should consider the possibility of orchiopexy and testicular prosthesis implantation to decrease the risk of testicular torsion and negative psychological effects.

KEYWORDS: Testis; Cryptorchidism; Gonadal dysgenesis, Orchiopexy; Histopathology

DOI: [1029252/Jcbr.4.2.15](https://doi.org/10.29252/Jcbr.4.2.15)

INTRODUCTION

Testicular regression syndrome (TRS) is defined as the partial or total absence of testicular tissue, either unilateral or bilateral, with or without rudimentary epididymis and spermatic cord in 46XY males. The supposed mechanism is due to atrophy and disappearance of an initially normal testis in the intrauterine life (1). The presence of the spermatic cord indicates presence of the testis in the early fetal life. When the absence of testis is associated with a blind ending spermatic cord, this entity is named as the ‘vanishing testis syndrome’ and is assumed to be a consequence of intrauterine or perinatal torsion or infarction (2, 3). In case of non-palpable testis, surgical exploration is advised and orchiopexy should be done if the gonad is found. Otherwise, removal of the remaining structures for histological analysis is recommended (4, 5). Among the histological findings, presence of a fibrovascular nodule is considered a mandatory diagnostic criterion for TRS. Other findings that re-enforce the diagnosis of TRS include the spermatic cord structures (testicular artery, pampiniform plexus, nerves and vas deferens), dystrophic calcification, hemosiderin deposits and rudimentary epididymis (6).

In this report, we present a case of an infant who underwent surgical exploration with an initial diagnosis of cryptorchidism after clinical examination in a neonatal clinic and histopathological examination confirmed the diagnosis of TRS.

CASE PRESENTATION

We present a case of a one-year old male who came to the outpatient clinic at Al Emadi Hospital, Doha, Qatar. Physical examination revealed normal external genitalia with palpable right testis and non-palpable left testis. The initial diagnosis was cryptorchidism. Ultrasound scanning of the scrotum revealed a normal testis that was seen in the right tunica vaginalis sac

measuring about 14×9×8 mm, while the left testis was not seen in the left tunica vaginalis sac. However, a small hypoechoic focus about 10×3×2.6 mm with small cord-like structure leading to it was seen in the left inguinal region near the superficial ring. The patient underwent left inguinal surgical exploration and a fibrous nodule with attached cord (Figure 1A) was removed and later sent for histological examination. Gross histological examination described a firm tissue fragment measuring about 2.5×0.7 cm with fibrous cut sections and attached cord-like structure sized approximately 4×0.2 cm. All tissue sections were submitted and subjected to microscopic examination. The histological sections revealed a highly vascularized fibrous nodule (Figure 1B), foci of dystrophic calcification (Figure 1C), hemosiderin deposits (Figure 1D) and a muscular tubular structure with a lumen lined by low columnar epithelium (hypoplastic vas deferens) (Figure 1E). No seminiferous tubule was identified, although a focus of hyalinized structure was noticed (Figure 1F).

DISCUSSION

Testicular regression syndrome (also known as vanishing testis or XY gonadal dysgenesis syndrome) is characterized by unilateral or bilateral atrophy and disappearance of an initially existed testis in the fetal life, which may vary from normal male with unilateral non-palpable testis through a phenotypic male with a micropenis to a phenotypic female. The possible mechanism of this condition may be in-utero torsion or infarction of the testis (4). Depending on the time of testicular development arrest during intrauterine life, five subtypes have been documented; gonadal aplasia, early fetal testicular dysgenesis, early, mid and late testicular regression. The incidence of TRS has been estimated to be less than 5% in patients with

cryptorchidism (7). Vanishing testis is more common than testicular agenesis in patients with unilateral non-palpable testis (8). In contrast, bilateral TRS is very rare (9) and a genetic predisposition to the intrauterine destruction of the testes, although not confirmed, cannot be ignored (10). Failure to discover the gonads at the time of exploration in cases with spermatic cord duct structures can happen if the gonad has undergone regression or when the surgeon fails to localize it. The pathologist can help in the management of these patients. Since 95% of testes are localized at or below the internal inguinal ring, a histopathological confirmation of the presence of spermatic cord and regressed testis on tissues removed at the primary inguinal exploration can reassure accurate diagnosis (11). In our case, the histopathological evaluation showed highly vascularized fibrous nodule with foci of dystrophic calcification, hemosiderin deposition and tubular structure with a lumen lined by low columnar epithelium (vas deferens). In line with these findings, Ali and Mathew mentioned that the diagnostic criteria for TRS require the presence of paratesticular structures in addition to fibrosis of testicular tissue (12).

Smith et al. studied 77 cases of TRS and reported a dystrophic calcification and haemosiderin deposits with no evidence of viable testicular tissue, but with relatively normal spermatic cord elements (1). Bader et al. reported that the common histological criteria for diagnosis of TRS are the presence of a blind-ending vas deferens, small fibrovascular nodule, calcification and hemosiderin (6). However, some studies have suggested the presence of blind-ending structures of the spermatic cord as a minimum criterion. In our case, no seminiferous tubule was identified although a focus of hyalinized structure was noticed. This finding is in line with findings of the study by Ali and Mathew (12). Regarding the etiology of TRS, the theory of an ischemic event in early or late fetal life is

the most accepted because findings such as fibrosis, dystrophic calcification and hemosiderin deposits corroborate this hypothesis (6). Theoretically, TRS increases the possibility of malignant changes within time and therefore removal of remnant tissue is a common practice to eliminate this risk (5). Thus far, only one case with intratubular germ cell neoplasm has been reported in the literature, a 9-year old boy with intratubular germ cell neoplasia in the testicular remnant, which signifies early malignant transformation (13). Some authors claim that the surgical fixation of contra lateral testis may reduce risk of testicular torsion, thus ensuring good chances of fertility (5). It is well-demonstrated that the loss or absence of testis can have negative psychological effects on adult men or children. Therefore, surgery for testicular prosthesis implantation is a good solution, providing similarity in the appearance, size and weight to the natural testis (14).

CONCLUSION

When patient fulfills clinical and pathological criteria for TRS, we should consider the possibility of orchiopexy and testicular prosthesis implantation to decrease the risk of testicular torsion and negative psychological effects for the patient.

DECLARATIONS

Funding

Not applicable.

Ethics approvals and consent to participate

Written informed consent was obtained from parents of the patient. All clinical investigations were conducted according to the principals of the Helsinki Declaration.

Conflict of interest

The author declares that there is no conflict of interest regarding publication of this article.

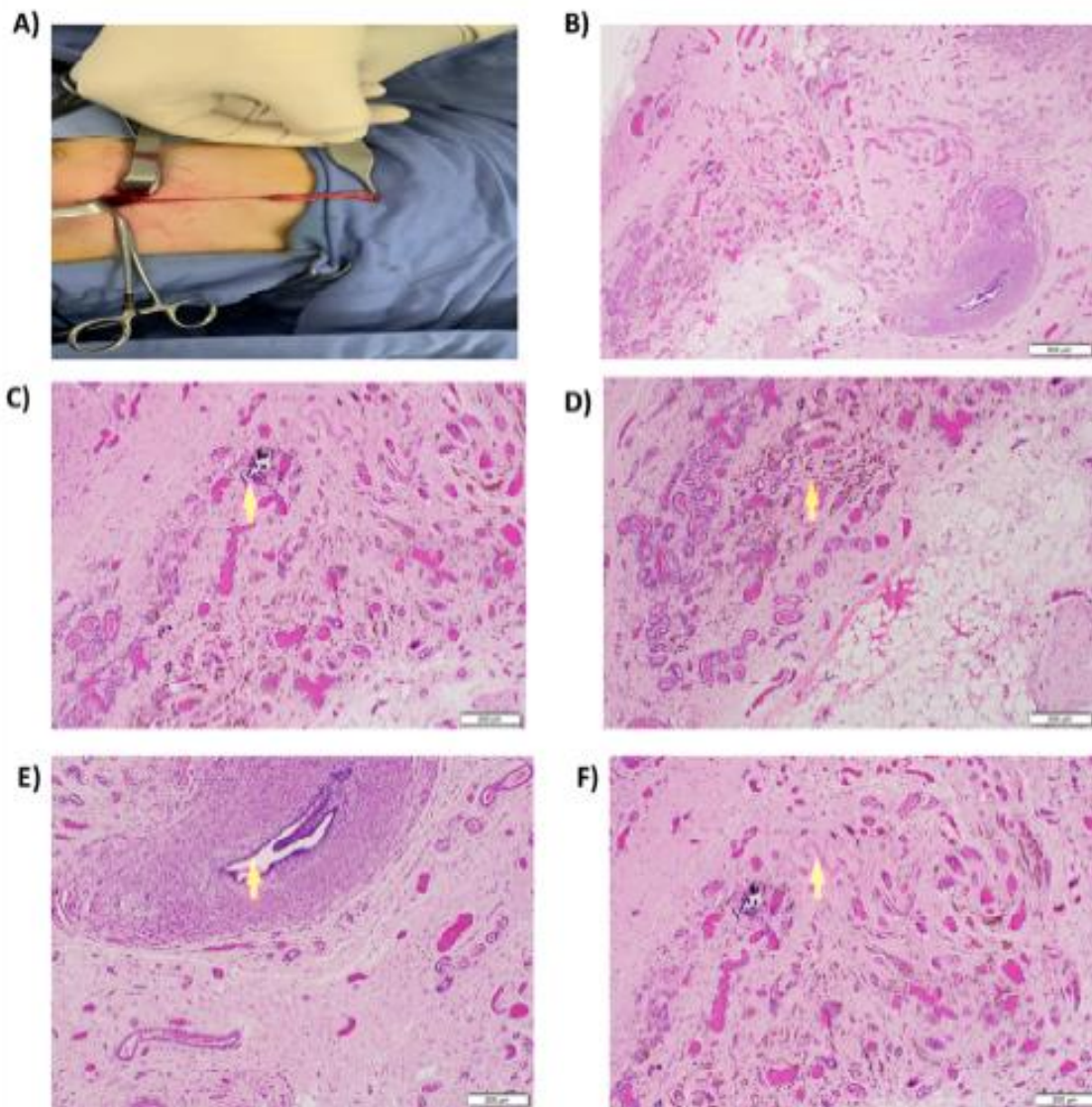


Figure 1. The surgical and histological assessment of the patient.

A) Left inguinal surgical exploration revealed a fibrous nodule with attached cord. B) Highly vascular fibrous nodule shows calcification, hemosiderin pigment and vas deferens (hematoxylin and eosin staining, 40X magnification). C) Foci of dystrophic calcification (arrow) (hematoxylin and eosin staining, 100X magnification). D) Hemosiderin pigment (arrow) (hematoxylin and eosin staining, 100X magnification). E) Hypoplastic vas deferens (arrow) (hematoxylin and eosin staining, 100X magnification). F) Foci of hyalinized structure (arrow) (hematoxylin and eosin staining, 100X magnification).

REFERENCES

1. Smith NM, Byard RW, Bourne AJ. Testicular regression syndrome a pathological study of 77 cases, individuals with normal external genitalia. *Histopathology* 1991; 19:269-72. [[DOI:10.1111/j.1365-2559.1991.tb00033.x](https://doi.org/10.1111/j.1365-2559.1991.tb00033.x)]
 2. Diamond DA, and Caldamone AA. The value of laparoscopy for a 106 impalpable testis relative to clinical presentation. *J Urol* 1992; 148:632-634. [[DOI:10.1016/S0022-5347\(17\)36675-2](https://doi.org/10.1016/S0022-5347(17)36675-2)]
 3. Pirgon O, and Dundar BN. Vanishing testes: a literature review. *J Clin Res Pediatric Endocrinol* 2012; 4:116-120. [[DOI:10.4274/Jcrpe.728](https://doi.org/10.4274/Jcrpe.728)]
 4. Spires SE, Woolums CS, Pulito AR, Spires SM. Testicular regression syndrome. a clinical and pathologic study of 11 cases. *Arch Pathol Lab Med* 2000; 124:694-8.
 5. Nistal M, and Paniagua R. Non-neoplastic diseases of the testis. *Urologic surgical pathology*. 2nd ed. Mosby Elsevier; 2008. p632 5. [[DOI:10.1016/B978-0-323-01970-5.50014-2](https://doi.org/10.1016/B978-0-323-01970-5.50014-2)]
 6. Bader MI, Peeraully R, Ba'Ath M, McPartland J, Baillie C. The testicular regression syndrome, do remnants required routine excision? *J Pediatr Surg* 2011; 46:384-6. [[DOI:10.1016/j.jpedsurg.2010.11.018](https://doi.org/10.1016/j.jpedsurg.2010.11.018)]
 7. Kogan S, Hadziselimovic F, Howards SS, Synder HM III, Huff DS. Pediatric andrology. In: *Adult and Pediatric Urology* 1996:2623-2674.
 8. Merry C, Sweeney B, Puri P. The vanishing testis: anatomical and histological findings. *Eur Urol* 1997; 31:65-67. [[DOI:10.1159/000474420](https://doi.org/10.1159/000474420)]
 9. Nishizawa S, Suzuki K, Tachikawa N, Nukui A, Kumamaru T, Shioji Y, et al. The vanishing testis: diagnosis and histological findings. *Nihon Hinyokika Gakkai Zasshi* 2000; 91:537-541. [[DOI:10.5980/jpnjurol1989.91.537](https://doi.org/10.5980/jpnjurol1989.91.537)]
 10. Ambulkar PS, Waghmare JE, Tarnekar AM, Shende MR, Ghosh SK, Pal AK. positive 46, XY male with vanishing testis syndrome, feminization and gynecomastia. *Nepal Med Coll J* 2012; 14:1-4.
 11. Desai A, Verma R, Parab M. A Case of Testicular Regression Syndrome. *The Internet Journal of Surgery* 2008
 12. Desai A, Verma R, Parab M. A Case of Testicular Regression Syndrome. *The Internet Journal of Surgery* 2008
 13. Ali M S., Mathew M., Testicular Regression Syndrome: Useful Diagnostic Approach *IOSR Journal of Dental and Medical Sciences (IOSR-JDMS)* e-ISSN: 2279-0853, p-ISSN: 2279-0861. Volume 17, Issue 1 Ver. 13 January. (2018), PP 07.
 14. Rozanski T.A, Wojno K.J, Bloom D.A. The remnant orchiectomy. *J Urol* 1996; 155: 712-714. [[DOI:10.1016/S0022-5347\(01\)66507-8](https://doi.org/10.1016/S0022-5347(01)66507-8)]
 15. Bodiwala D, Summerton DJ, Terry TR. Testicular prosthesis: development and modern usage. *Ann R Coll Surg Engl*. 2007;89(4):349-53. [[DOI:10.1308/003588407X183463](https://doi.org/10.1308/003588407X183463)]
- How to Cite:** Nasr ali S, Mohammed Omar A M R, Alhama H. Clinical and Histopathological Evaluations of Testicular Regression Syndrome: A Case Report. *jcbr*. 2020; 4 (2)